www.fetalcarecenter.org • 1-888-FETAL59

Congenital Diaphragmatic Hernia (CDH)

What is a congenital diaphragmatic hernia (CDH)?
CDH is a defect in the diaphragm of the fetus. The diaphragm is the muscle and tissue that separates the chest and abdominal cavities.

In CDH, abdominal organs push into the chest cavity through the defect (or herniate), compressing the developing lungs. This results in severe pulmonary hypoplasia (arrested development of the lungs), causing the lungs to remain below normal in size and underdeveloped.

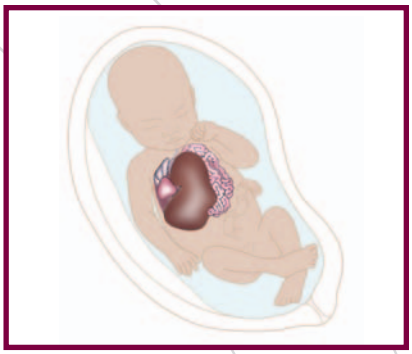

Above is an illustration of CDH with bowel and liver herniated into the chest.

What causes congenital diaphragmatic hernia (CDH)?
The cause of CDH is thought to be failure of the diaphragm to develop at nine to 10 weeks of gestation. When closure does not occur, the intestinal organs may herniate into the chest cavity through the defect in the diaphragm. What causes the failure of the diaphragm to close is unknown.

What is the incidence of congenital diaphragmatic hernia (CDH)?
The incidence of CDH is estimated at one in 2,200 births. Survival rate depends, in large part, on the delivery at or the immediate transfer to a tertiary-care hospital where the newborn can be treated promptly by a staff skilled in CDH care.

How is congenital diaphragmatic hernia (CDH) diagnosed?
An ultrasound can detect signs of CDH. Physicians closely examine the entire chest and abdominal area to look for what can be very subtle signs of CDH. This diagnosis can also be aided by fetal MRI.

How is pregnancy managed when congenital diaphragmatic hernia (CDH) is suspected?
If CDH is suspected, the mother should undergo a detailed ultrasound to confirm the diagnosis and detect associated abnormalities. Prenatal karyotyping (the study of the chromosomes of cells) is recommended because of the high incidence of associated chromosomal abnormalities. Fetal echocardiography is recommended in all cases of CDH because of the increased incidence of congenital heart disease. Fetal MRI should be obtained to define the severity of CDH.

What are the fetal interventions for congenital diaphragmatic hernia (CDH)?
The majority of babies with CDH will do very well with postnatal treatment in tertiary centers skilled in the management of CDH.

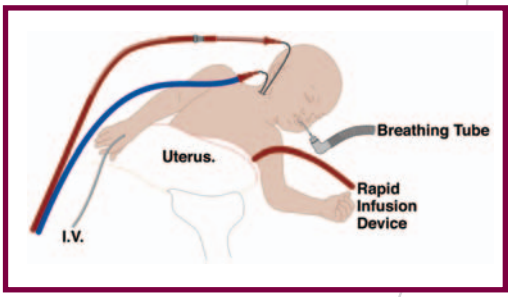

Above is an illustration of EXIT-to-ECMO

In select cases, fetal intervention is available for the most severely affected fetuses with very large hernias that have a poor prognosis.

Depending on the nature of the CDH, the fetus may be a candidate for reversible balloon tracheal occlusion or EXIT-to-ECMO (ex utero intrapartum treatment to extracorporeal membrane oxygenation) procedures, both of which are types of fetal surgical intervention.

Contact the Fetal Care Center of Cincinnati

For more information, please call 1-888-FETAL59
or email us at info@fetalcarecenter.org.

Fetal Care Center of Cincinnati