

Fecal Incontinence Types

The medical definition of [fecal incontinence](#) is simplistic. In fact it is defined as "the incapacity to voluntarily hold the feces." Usually, we can divide fecal incontinence into two categories:

1. Real fecal incontinence
2. Pseudo-incontinence

Real Fecal Incontinence

In the case of real fecal incontinence, the normal mechanism of the bowel control is damaged. An alteration of the muscles which surround the anorectal canal along with poor sphincters (those muscles which control the anus) are responsible for fecal incontinence in children operated on for anorectal malformations with bad prognosis.

The innervation (supply of nerve connections) of these muscles are important for their correct function. A deficit of the innervation occurs in anorectal anomalies as well as in other conditions.

For example, in cases of spina bifida, the contraction and relaxations of the muscles, as well as sensation are both deficient. Thus the presence and the passage of stool, and the perception of the difference between solid and liquid stool and gas is interrupted.

Pseudo-Incontinence

In the situation of pseudo-incontinence, the child behaves like he / she is fecally incontinent. Further study, however, shows that he / she suffers from severe constipation and fecal impaction. Amazingly, when the impaction is treated and the patient receives enough laxatives as to avoid constipation, he / she becomes continent.

It is extremely important to distinguish between real incontinence and pseudo-incontinence to identify the origin of the problem and, consequently, to plan the best treatment.

As previously stated, 75 percent of children operated on for an [anorectal malformation](#) will have voluntary bowel movements. Out of them, half will not soil and their parents are encouraged to prevent constipation.

The other half of these children may soil, and treating the constipation makes the soiling disappear. Occasionally these children require [bowel management](#) when the soiling is troublesome.

Children Who are Candidates for Reoperation

Children who are candidates for a reoperation were previously operated on for an imperforate anus and now have fecal incontinence. A second operation with the hope of obtaining good bowel control can be performed if the following conditions are met:

1. The child was born with a good sacrum, good sphincter mechanism and a malformation with good functional prognosis.
2. There is evidence that the rectum is completely mislocated.
3. The child has the full length of his / her colon.

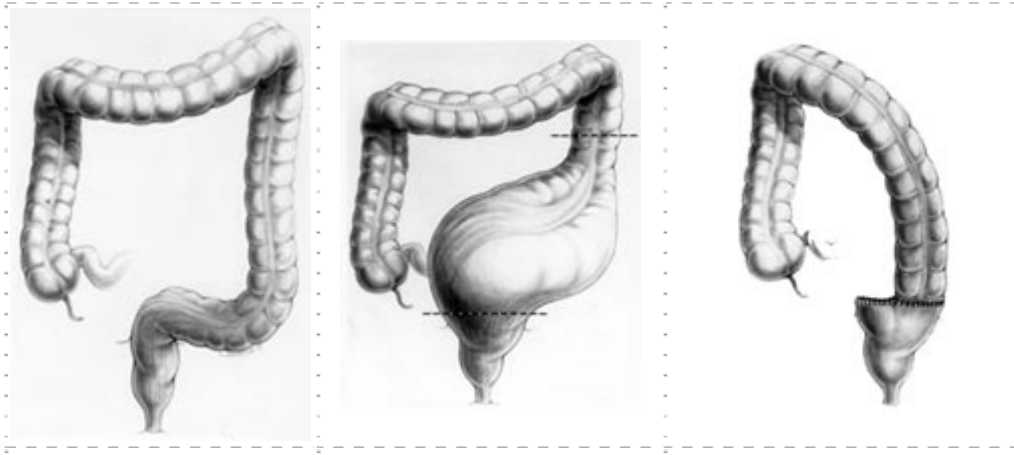
A [posterior sagittal anorectoplasty / PSARP](#) can be performed, and the rectum can be relocated within the limits of the sphincter mechanism. In this case, approximately 50 percent of the children operated on under these circumstances have a very significant improvement in bowel control to the point that they do not require bowel management to remain clean.

Children with Pseudo-Incontinence

Most of these children suffer from different degrees of dilatation of the normal rectum and sigmoid, a condition defined as megarectosigmoid.

There is also evidence that these children suffer from a hypomotility disorder that interferes with complete emptying of the rectosigmoid.

These children are born with a good prognosis type of defect and underwent a technically correct operation, but did not receive appropriate treatment for constipation. They therefore developed fecal impaction and overflow pseudo-incontinence.



Normal Colon Graphic · Megarectosigmoid Picture · Resected Colon Illustration

The Fecaloma needs to be removed with enemas and colonic irrigations (usually an aggressive program of enemas) to clean the megarectosigmoid. Subsequently, the constipation is treated with the administration of large doses of laxatives.

The dosage of the laxative is increased every day until the right amount of laxative is reached in order to empty the colon completely every day.

Once the constipation is treated adequately, if the child still cannot control the stool, then we conclude that he / she suffers from real incontinence and constipation. He / she cannot be treated with laxatives, but rather needs the bowel management for fecal incontinence that will be described here.

On the other hand, once the constipation is treated adequately, if it becomes evident that the child is actually continent we then conclude that he / she suffers from overflow pseudo-incontinence.

If medical treatment proves to be extremely difficult because the child has a severe megasigmoid and requires an enormous amount of laxatives, the surgeon can offer a surgical alternative consisting of a resection of the sigmoid colon.

Before offering these children a sigmoid resection it is mandatory to confirm that they are suffering from overflow pseudoincontinence rather than real fecal incontinence with constipation.

Failure to make this differentiation may lead to an unnecessary operation; a fecally incontinent constipated child subjected to this operation would be changed to one with diarrhea, who is much more difficult to manage.

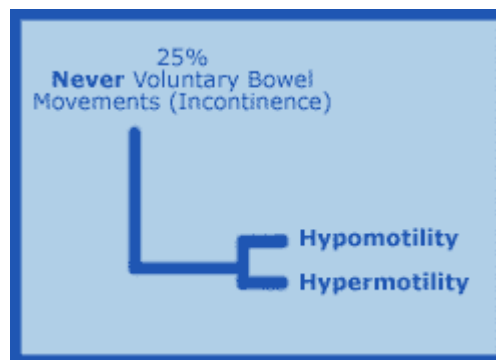
As a result of this operation, the laxatives required to treat these children can be significantly reduced or even abolished.

Children Who are Candidates for Bowel Management

Children who suffer from fecal incontinence after the repair of an imperforate anus are usually those born with a bad prognosis type of defect and severe associated defects (defect of the sacrum, poor muscle complex).

However, children who were born with a poor prognosis type of defect may still enjoy a good quality of life when treated with a bowel management program.

Children operated on for imperforate anus and suffer from fecal incontinence can be divided into two well defined groups that require individualized treatment plans.



Children with Constipation / Colonic Hypomotility

In these children the motility of the colon is significantly reduced. The basis of the bowel management is to teach the parents to clean the child's colon once a day by the use of a suppository, an enema or a colonic irrigation.



No diet or medication is necessary in these cases. The fact that they suffer from constipation / hypomotility guarantees they will remain clean in between enemas. The real challenge is only to find out the right enema capable of cleaning the colon completely.

Soiling episodes or severe "accidents" occur by an incomplete cleaning of the bowel with feces that progressively accumulates into it.

Children with Loose Stools and Diarrhea

The great majority of children who suffer from this kind of problem have been operated on before 1980, which means before the introduction of the Posterior Sagittal Anoplasty / PSARP technique. In those years the techniques frequently included resection of the rectosigmoid (reservoir).

Therefore, this group of children have an overactive colon. Rapid transit of stool results in frequent episodes of [diarrhea](#). This means that even when an enema cleans their colon rather easily, stool keeps on passing fairly quickly from the cecum to the descending colon and the anus. To prevent this, a constipating diet and / or medications to slow down the colon are necessary.

Eliminating foods that further loosen bowel movements will help to prevent the colon to move fast. Some children, however, may have in addition an "irritable" colon which makes the management more challenging.

Contact the Colorectal Center at Cincinnati Children's

For more information or to request an appointment for the Colorectal Center at Cincinnati Children's Hospital Medical Center, please [contact us](#).