

# Idiopathic Constipation: What is it?

## Definition of Idiopathic Constipation

Idiopathic constipation refers to incapacity to regularly pass stool. There are many terms used to describe this problem and there is much confusion about patients. Some of the terms used include "internal sphincter achalasia," "short segment or low segment Hirschsprung's disease" and "intestinal pseudoobstruction." Since the cause remains unknown, we prefer to utilize the global term "idiopathic constipation." The cause is unknown. It is one of the most common bowel movement disorders among children.

### View a Video

View a [video presentation on Idiopathic Constipation](#) by colorectal surgeon, Marc A. Levitt, MD.

The severity of idiopathic constipation varies. It can be a very mild problem solved by changes in diet and re-education of the patient or it can be a very severe disorder requiring high doses of laxatives and in extremely severe cases, an operation. Idiopathic constipation can be treated but not cured.

## Cause and Origin of Idiopathic Constipation

The term "idiopathic" means that the origin of the problem is unknown. There are many theories, but none of them explains the problem satisfactorily.

## Idiopathic Constipation Symptoms

While we do not know the real nature or origin of idiopathic constipation, we know the natural history and also the severe secondary consequences that occur when this condition is not treated adequately. Rigorous investigation usually shows that the patient has suffered from constipation since very early in life.

Breast feedings provoke a laxative effect; therefore, most breast-fed babies do not show symptoms of constipation until breast feedings stop.

Most baby formulas promote constipation and the initiation of these may mark the beginning of the symptoms of constipation.

Constipation may be very mild to start with but eventually, when a child suffers the first episode of fecal impaction (meaning that he goes 1-3 days without passing stool) he forms a rock hard piece of stool inside his rectum which eventually is expelled. This can be a very painful experience.

The discomfort can increase, with time the patient retains stool again and eventually, the child has a more painful bowel movement. Often, a cut in the anus occurs during the passing of a large, hard piece of stool. This cut, called fissure, is reopened each time the child passes more stool.

As a result, the child feels that having a bowel movement is painful and avoids it. He / she voluntarily holds the stool which, of course, worsens the problem. The retained stool becomes larger and harder and when it is eventually passed, provokes pain and bleeding. This creates a cycle, making the problem more difficult to treat. (Fig. 1)

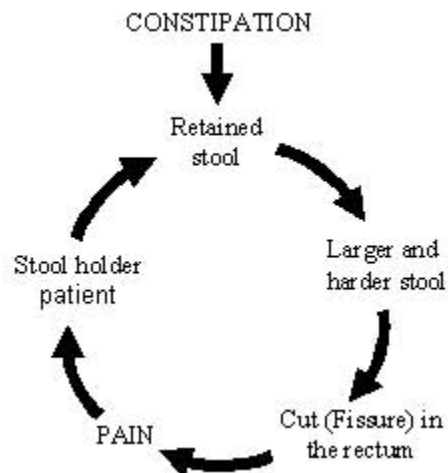


Fig. 1

At this point, many parents go to their pediatricians who perform a rectal examination; this is, of course, another painful maneuver which may reopen a fissure.

When stool stays inside the rectum longer than 24 hours, the rectum enlarges in order to accommodate a large amount of stool. When this problem continues for long periods of time, the rectum and colon grow enormously. This condition is referred to as "megarectosigmoid."

There is scientific evidence which shows that when a piece of bowel (rectum and sigmoid) becomes very dilated, it loses its' efficiency to pass stool. Peristalsis is disturbed when the bowel

is dilated beyond a certain point. In other words, constipation provokes megarectosigmoid, which in turn provokes more constipation.

Idiopathic constipation is a self-aggravating problem. It is important for parents to understand this in order to help their child. (Fig. 2)

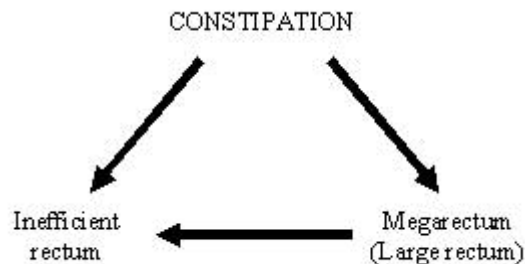


Fig. 2

Fecal impaction occurs when a patient carries a large amount of stool inside his / her rectum. As a result, he / she passes tiny amounts of solid stool accidentally through the anus.

This is also called encopresis. This causes constant soiling of the underwear. When this occurs at school, it becomes a very serious problem which makes the child feel socially unaccepted.

At this point, the child develops more serious secondary psychological problems because of rejection by his / her classmates. The child becomes accustomed to having underwear dirty with stool. The smell is very obvious to everyone around the child, but the child gets used to the odor.

## Natural History of Idiopathic Constipation

The natural history shows idiopathic constipation is manageable but not curable. We have seen many patients improve but there is little documentation of any real cures.

## Diagnostic

A rectal exam is performed to rule out any conditions, such as an anal narrowing, which might require surgical treatment. This is rare. A rectal exam also allows the physician to feel for any stool sitting in the anus.

An empty rectum in a patient with severe constipation is frequently a manifestation of another condition called [Hirschsprung's disease](#).

A study called [contrast enema](#) without barium is ordered and usually shows a very dilated colon (megarectosigmoid). In a typical case of idiopathic constipation, the megarectosigmoid extends all the way down to the anal margin.

This is completely different from Hirschsprung's disease in which one can see a rather narrow rectum and the megasigmoid is located above inside the abdomen. (Figures 3 and 4)



Fig. 3 – Idiopathic constipation

It is also important to rule out other conditions which may provoke constipation such as metabolic disorders (hypothyroidism), spinal disorders, spina bifida, presacral tumors and sacral abnormalities. For this we usually take more specialized tests.

The overwhelming majority of patients with constipation belong to the category of idiopathic, meaning there is no recognizable problem causing constipation.

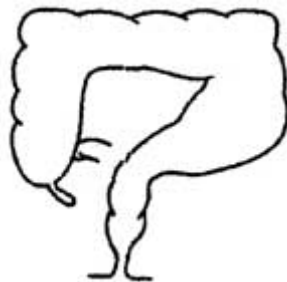


Fig. 4 – Hirschsprung's Disease

## Medical Management of Idiopathic Constipation

The management of idiopathic constipation requires parents to understand the nature of the disease. Idiopathic constipation requires prolonged treatment with the hope of reversing the vicious cycle already described making the condition more manageable.

The goal is to manage the emptying of the rectum with diet or laxative. When children reach the age of 10 or 12 years and can understand the goals of the treatment, they usually can take care of themselves.

### Step 1 in Treating Idiopathic Constipation

The first part of the treatment consists of dislodging the stool. This requires the use of repeated enemas and can take 1 - 4 days.

In severe cases, we may administer a special solution through a nasogastric tube to provoke diarrhea until all stool exits the body. In very severe cases, a trip to the operating room may be necessary to manually dislodge the stool while the child is under anesthesia.

### Step 2 in Treating Idiopathic Constipation

Once the stool is dislodged, management with laxatives is started. Laxatives are medications that promote bowel motion. It is essential, therefore, to take care of the fecal impaction before starting the treatment with laxatives to avoid cramping.

One important basic principle is to recognize that each child needs a different amount of laxative. We determine the amount of laxative that a child needs by trial and error.

The amount of laxatives that children need is frequently much higher than the recommended dosage. If a child can be managed with the use of laxative-type foods, then we prefer that method. Unfortunately, laxative-type foods only work for minor types of constipation.

Both, the results of the contrast enema and the physical examination of the patient usually give us some idea of the amount of laxative that the patient may need.

By the end of the following day, if the child has not voluntarily passed stool, it means the amount of laxative that was given was not enough and it then has to be increased.

Most importantly, it means he already has stool from the food that he ingested the day before in his rectum which now has to be removed with an enema to avoid fecal impaction.

If the child passes stool it means that he does not need an enema and that the desired amount of laxative has already been reached for this child. The parents should then administer this amount daily to help the child have bowel movements every day.

If the child suffers from diarrhea, it may mean that the amount of laxative is too much and it should now be reduced slightly. The final dose is always decided upon by trial and error. (Figure 5)

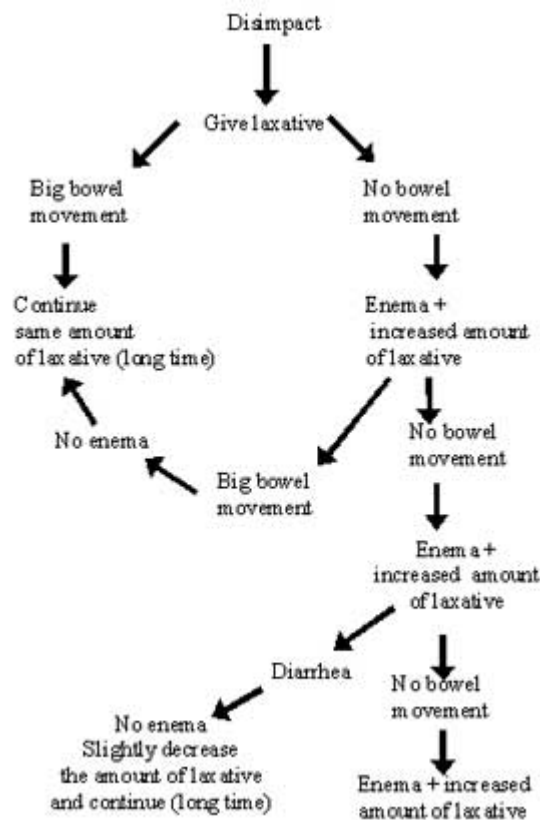


Fig. 5

### Step 3 in Treating Idiopathic Constipation

Once we have determined the dose of laxative that the child needs (usually a very large amount) the amount is continued for a long period of time (months).

During those months, parents are encouraged to give laxative-type foods to decrease the amount of laxative they are giving to provoke bowel movements with the most natural means.

Trying to control a constipated child with diet only is difficult because sometimes the child is not consistent in eating the types of food we want him to eat. As the child grows, sometimes the amount is increased.

## Surgical Options

Patients with severe intractable constipation are given the option of an operation called sigmoid resection (Figure 6) which alleviates the problem of constipation or at least helps reduce the amount of laxatives that the patient needs.

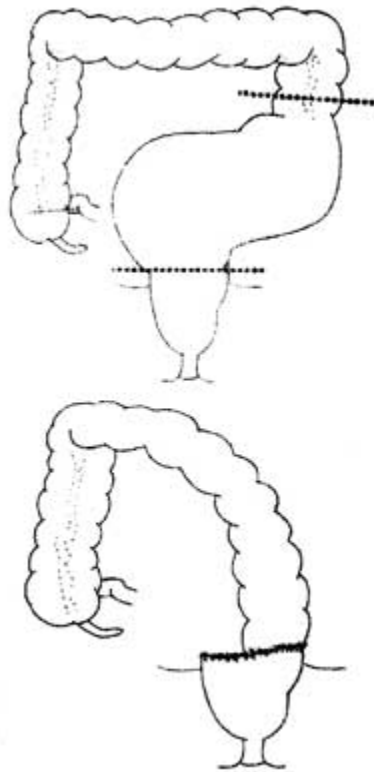


Fig. 6



## Contact the Colorectal Center at Cincinnati Children's

For more information or to request an appointment for the Colorectal Center at Cincinnati Children's Hospital Medical Center, please [contact us](#).