

Ovarian Cysts in Pubertal Patients



FAST FACTS

In adolescents, **most ovarian cysts are benign** and will resolve spontaneously

~1/3

of patients with ovarian cysts will present with pain, though most are diagnosed incidentally

WHEN TO REFER

Refer as follows to Cincinnati Children's Gynecology:

- If patient is premenarchal
- Simple cyst ≥ 8 cm
- Complex cyst
- Persistent symptoms or stable/enlarged cyst on follow-up ultrasound

With a referral, it is beneficial to send ultrasound images and report.

If acute, severe abdominal pain, nausea, vomiting refer to Cincinnati Children's Emergency Department for evaluation.

If you have non-urgent clinical questions about patients with ovarian cysts, email gynecology@cchmc.org.

As the hormonal signals between the brain and ovaries develop in adolescence, the formation of ovarian cysts (dominant follicles) is common and often physiologic.

Follicular cysts are simple cysts which are a normal physiological finding during the menstrual cycle when a developing follicle does not ovulate. After ovulation, follicles become a corpus luteum and can become hemorrhagic (containing a small amount of blood).

| Benign | Malignant |
|--|--|
| <p>Simple</p> <ul style="list-style-type: none"> • Follicular/simple • Cystadenoma • Paraovarian/paratubal <p>Complex</p> <ul style="list-style-type: none"> • Mature teratoma • Endometrioma • Cystadenofibroma • Tubo-ovarian abscess | <ul style="list-style-type: none"> • Sex cord stromal (e.g., granulosa cell tumor) • Germ cell (dysgerminoma, immature teratoma) • Epithelial |

ASSESSMENT

Perform a standard health history and physical exam (HPE) with probing questions regarding pubertal status, and review or obtain pelvic ultrasound (transabdominal). Pelvic exam is generally not indicated.

HPE RED FLAGS

Situational History

- Premenarchal
- Virilization/voice deepening
- Acute, severe abdominal pain, nausea, vomiting

Patient History

- History of bleeding tendencies (frequent nosebleeds, bruises easily or prior hemorrhagic cysts)
- History of ovarian torsion
- History of oophorectomy or unilateral ovary

Family History

- Familial/hereditary cancer predisposition (e.g., DICER-1)
- Family history of bleeding disorder

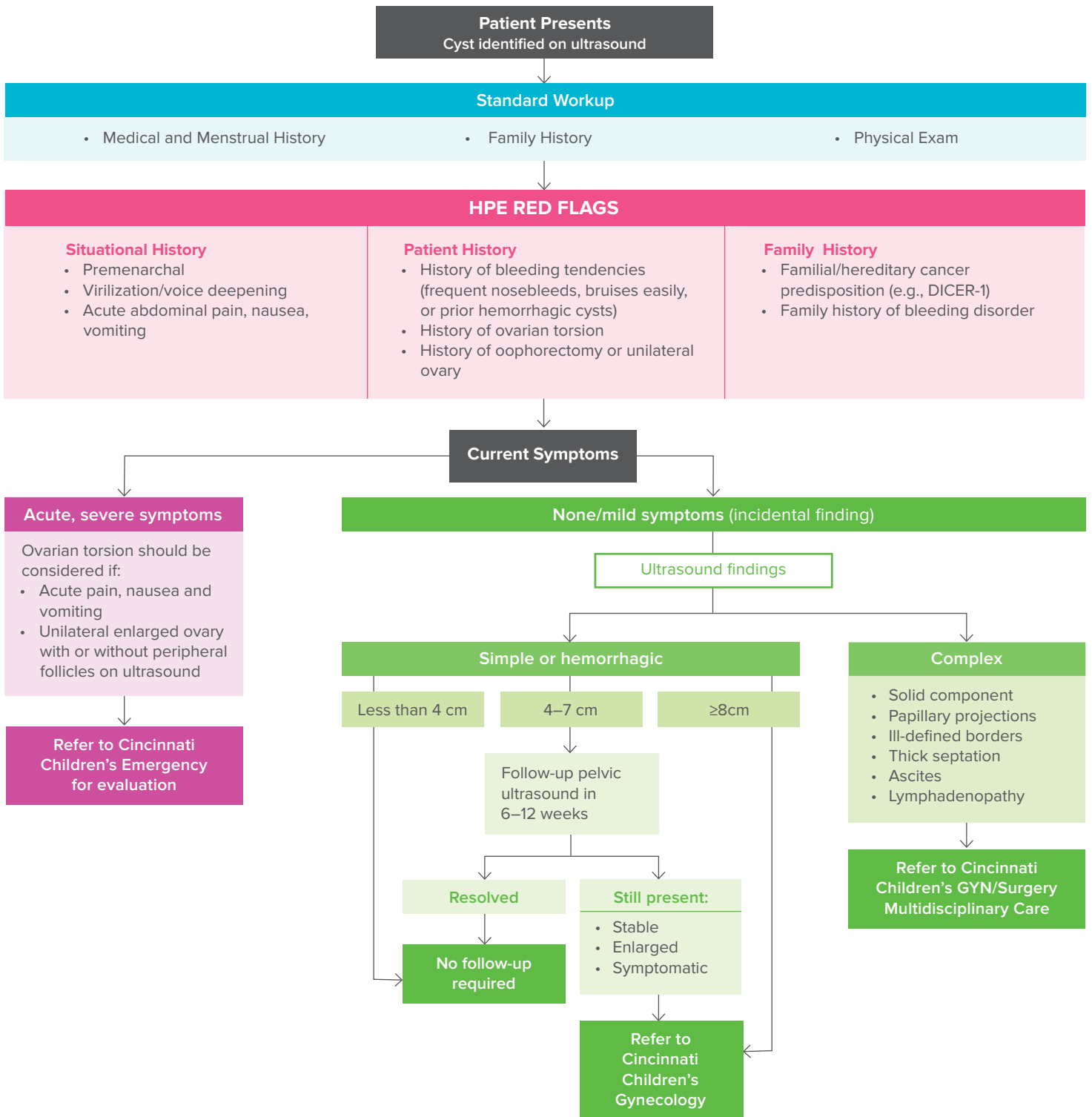
MANAGEMENT/TREATMENT

Consider patient symptoms and ultrasound findings in determining follow-up.

- If asymptomatic or mild symptoms and simple/hemorrhagic cyst:
 - Less than 4 cm, reassure patient
 - 4–7 cm, repeat pelvic ultrasound in 6–12 weeks
 - Greater than or equal to 8 cm, refer to Cincinnati Children's Gynecology
- If complex cyst, refer to Cincinnati Children's GYN/Surgery Multidisciplinary Care.
- If follow-up ultrasound shows stable/enlarged cyst or patient is symptomatic, refer to Cincinnati Children's Gynecology.

If you would like additional copies of this tool, or would like more information, please contact the Physician Outreach and Engagement team at Cincinnati Children's.

Ovarian Cysts in Pubertal Patients



For urgent issues, or to speak with the specialist on call 24/7, call the Physician Priority Link at 1-888-987-7997.