

Redundant Foreskin

FAST FACTS

>95%

of boys are born with physiological phimosis

~50%

of 3-year-old boys' foreskins can be retracted

~90%

of 5-year-old boys' foreskins can be retracted

1–5%

of males will have non-retractable foreskins by age 16 years

WHEN TO REFER

Refer to Cincinnati Children's Urology for further evaluation and management when:

- Suspected discomfort while urinating
- Foreskin fills with urine or balloons out during urination
- History of urinary tract infections in uncircumcised boy
- History of balanitis
- Suspected pain during erections
- Presence of penile adhesions or penile inclusional cyst in an uncircumcised boy
- Inability to pull foreskin back in an older boy
- History of paraphimosis

If you have clinical questions about patients with redundant foreskin, email PedsUrology@cchmc.org.

In uncircumcised boys, the foreskin covers the head of the penis. Physiological phimosis—where the foreskin doesn't yet retract fully—is normal in uncircumcised babies and toddlers. The foreskin begins to separate from the tip of the penis naturally between 2–6 years of age (sometimes later), allowing the foreskin to be retracted. If the separation does not happen, pathological phimosis may occur.

Redundant foreskin occurs when the circumcision leaves the foreskin too long or uneven, which can lead to problems including smegma buildup, inclusional cysts, balanitis (inflammation or infections of the foreskin) or penile adhesions (the penile shaft skin attaches to the head of the penis).

ASSESSMENT

Perform a standard history and physical examination focused on examination of genitalia with gentle pulling of the foreskin.

HPE (HISTORY AND PHYSICAL EXAM) RED FLAGS

- Foreskin fills with urine or balloons out during urination
- History of urinary tract infections in uncircumcised boy
- Foreskin or head of the penis becomes red, itchy or swollen
- Inability to retract foreskin in older child

MANAGEMENT/TREATMENT OF REDUNDANT FORESKIN

In an uncircumcised baby, parents should wash his penis with mild soap and water during each bath. Treat the foreskin gently and do not force it back, which could cause pain, tearing and/or bleeding. Once the foreskin can be retracted, clean regularly—gently pull back foreskin and clean beneath it with mild soap and water; rinse and dry beneath the foreskin thoroughly, then pull it back over the head of the penis.

Consider topical steroid ointment to help soften foreskin in older boys, age 5+ years, with physiological phimosis. Massage ointment into area around the glans and foreskin 2x/day for 4–6 weeks. Most commonly used: hydrocortisone 2.5%, betamethasone 0.05%, triamcinolone 0.01%, and fluticasone propionate 0.05%.

Consider circumcision if:

- Steroid ointment is unsuccessful
- Pathologic phimosis
- Paraphimosis (foreskin stuck in retracted position behind the head of the penis)
- Recurrent UTI
- Severe/recurrent balanoposthitis

Consider circumcision revision if any of the following are present in a previously circumcised boy:

- Significant redundant foreskin
- Penile adhesions
- Episodes of balanitis or pathological phimosis present

If you would like additional copies of this tool, or would like more information, please contact the Physician Outreach and Engagement team at Cincinnati Children's.

Redundant Foreskin

Inclusion Criteria

- Uncircumcised boy
- Redundant foreskin
- Penile adhesions

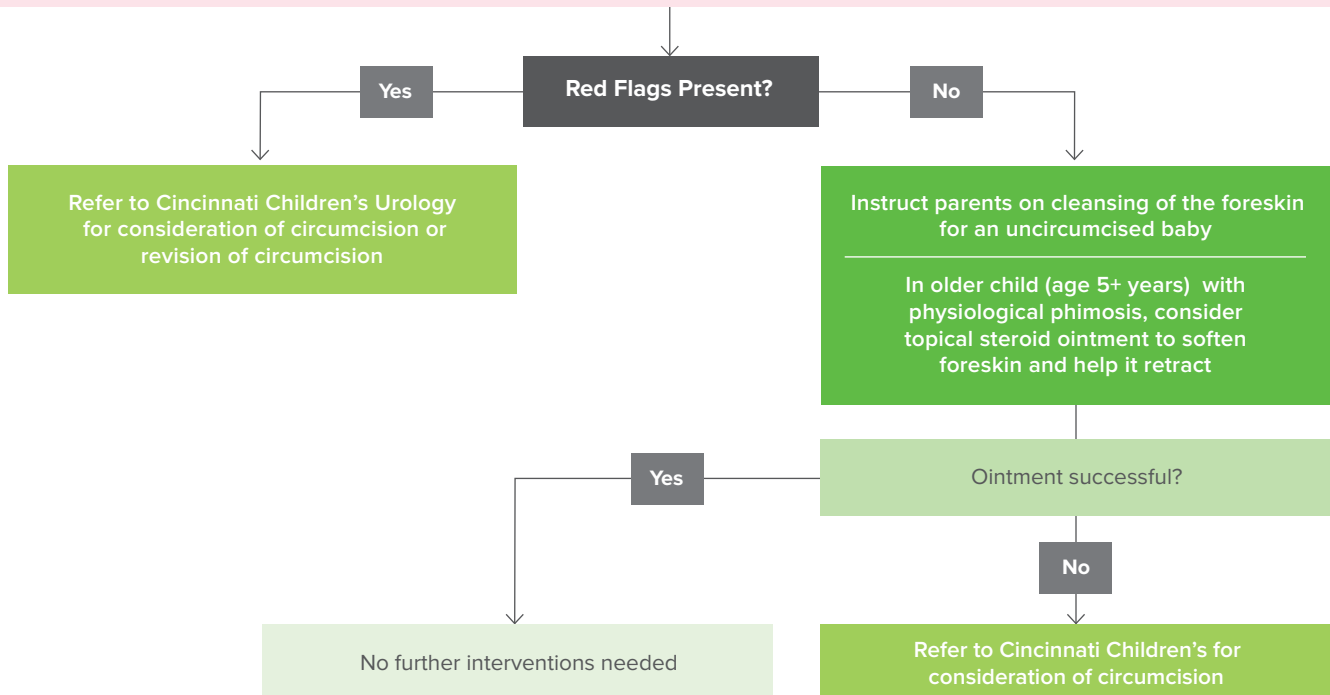
Patient Presents

Standard Workup

- Situational History
- Family History
- Physical Exam

HPE (HISTORY AND PHYSICAL EXAM) RED FLAGS

- Foreskin fills with urine or balloons out during urination
- History of UTI in uncircumcised boy
- Foreskin or head of the penis is itchy, red or swollen
- Inability to retract foreskin in older child



Note: Currently, there is no evidence-based consensus guideline on care of circumcised child.

For urgent issues, or to speak with the specialist on call 24/7, call the Physician Priority Link® at 1-888-987-7997.